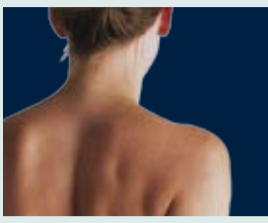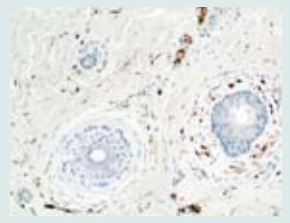



**page 1**  
Harvesting adipose cells for breast augmentation



**page 2**  
Intact lipocytes in WAL aspirates



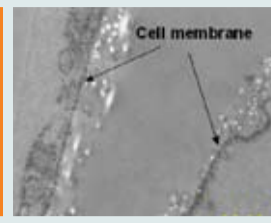
**page 2**  
New study: the water-jet is gentle and safe in all Ranges



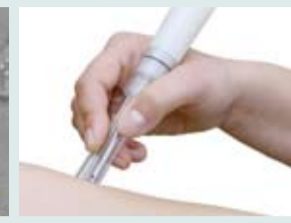**page 3**  
Clinical reports on safety



**page 3**  
How to use the body-jet® Ranges?



**page 3**  
Effect of the water-jet viewed by the electron microscope



**page 4**  
Wound debridement: safe and fast



**page 4**  
AquaShape® and body-jet® for gentle body contouring

## WAL and Autologous Fat Transfer: A new, effective autologous fat grafting method for breast augmentation

Interview with Klaus Ueberreiter M.D.,  
Asklepios Klinik Birkenwerder/Berlin  
by Inge Matthesen

**Question: What has triggered the introduction of this new fat transplantation method?**

Dr. Ueberreiter: Through the publications of Sydney Coleman in New York, micro-fat grafting has been gaining popularity since the mid-90s and is now being used worldwide for the correction of tissue deficits in the facial area. It wasn't long before the use of autologous fat for breast enhancement as an alternative to silicone implants was also being discussed.

**Question: Have advances since been made in the use of this method for breast augmentation?**

Dr. Ueberreiter: In March 2007, Coleman presented the results of a study on breast augmentation with autologous fat (1); Zocchi and Delay, from Italy and France, published additional findings. Since then, autologous fat transfer has been generally accepted as a surgical option for breast enlargement.

**Question: What are the disadvantages of previously used methods and the advantages of the new method you have developed?**

Dr. Ueberreiter: The previously used methods of micro-fat grafting with intermediate steps such as centrifugation are very time-consuming and associated with long

surgery times. Whereas fat cells that have been aspirated from tissues using the body-jet® are already washed, and the blood content of the aspirate is very low. In our studies, we have been able to prove that this fat contains the same number of vital fat cells and fat stem cells (preadipocytes) as the fat harvested using previous methods.

This is the first method for fat harvesting that requires only slightly more time for liposuction while significantly decreasing the overall procedure time.

**Question: Can you describe the method in a little greater detail?**

Dr. Ueberreiter: Fat removal with the body-jet® represents an especially gentle form of liposuction, as has since been substantiated in various publications, e.g. by Stutz, Araco and Meyer (2). We have been using this system successfully since 2004.

This success led to the idea of constructing a special collection system with additional filter function for the sterile collection of fat, an idea that was successfully implemented, thanks to the cooperation of human med AG. When the AquaShape® LipoCollector™ is used in combination with the body-jet®, the filtered, washed fat no longer has to be centrifuged and

can be used for reinjection without further preparation.

Another advantage lies in the fact that, with the WAL system (water-jet assisted liposuction), fat cells can be harvested through very thin lumina with openings of 0.9 mm. As a result, the fat cells in the transferred fat tissue are more finely distributed and can be better re-injected with the appropriately thin cannulas, which reduces the risk of fat necrosis and calcification.

**Question: Are you planning to publish the results you are achieving with this new method?**

Dr. Ueberreiter: Since October 2007, we have been conducting a prospective controlled study on breast augmentation; the results we have seen with the more than 30 patients who have undergone the procedure to date are very promising. These results are being examined using various tests, including imaging procedures (MRI), both prior to and six months after the surgery. After the study is completed in April 2009, we will analyze and publish the data.

**Question: For which patients is this method most suitable?**

Dr. Ueberreiter: The patients on whom this technique is being employed basically fall into three groups. The first group includes patients with primarily aesthetic desires for breast enlargement. Also, the procedure is very appropriate for filling defects and correcting asymmetries as well as in cases



where the patient cannot tolerate silicone implants in the long term and the implants must be removed. A third and very important area of application is breast reconstruction following breast cancer surgery.

**Question: Can you tell us a little more about possible fat regeneration and the number of fat grafts that are required?**

Dr. Ueberreiter: The first results are showing that an increase of breast volume of more than one cup size requires two fat grafts. For breast reconstruction following tumor resection, about four to five fat grafts are required, whereby this method is much less traumatic for the patient than a free tissue transfer, for example from the abdomen.



AquaShape® LipoCollector™

**Question: How long do the transplanted cells remain in the tissue?**

Dr. Ueberreiter: The integrated cells will remain in the tissue permanently. After approximately six weeks, about 80% of the transplanted cells have been integrated

into the host tissue.

**Question: Are there still problems associated with the masking or mimicking of possible tumor tissue in imaging procedures?**

Dr. Ueberreiter: No. There have been numerous reports published on this topic since the issue was first raised.

**Question: Dr. Ueberreiter, can you briefly summarize the advantages of this new procedure?**

Dr. Ueberreiter: The advantages lie in the fact that fat can be harvested (liposuction) and transferred (fat grafting) during a single operation. The entire procedure takes only about two hours. Furthermore, the vitality and the integration rate of the fat cells harvested using this gentle procedure are very good.

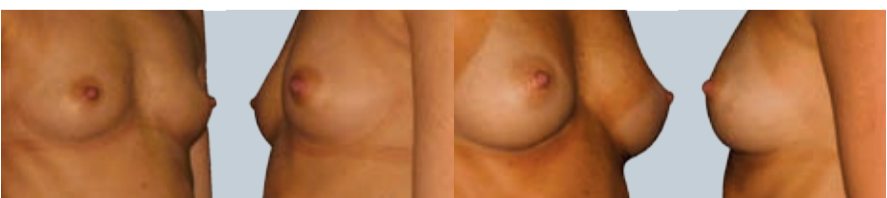
The entire surgery can be performed on an outpatient basis under local anesthesia with light sedation.

(1) Sydney Coleman, A. P. Saboeiro: Fat Grafting to the Breast Revisited: Safety and Efficacy. Plast. Reconstr. Surg. 119:775, 2007.

(2) Publications by Stutz, Araco and Meyer, please refer to pages 2 and 3 of this issue.

■ **Contact:**

Dr. K. Ueberreiter, Asklepios Klinik Birkenwerder/Berlin, Hubertusstrasse 12-22, 16547 Birkenwerder, Germany



## The influence of local anesthetics on the vitality of the pre-adipocytes

According to a study by Ueberreiter, Keck and Janke, the selection of the local anesthetic has a great impact on the vitality of the pre-adipocytes. In this investigation, human pre-adipocytes from the fat cell aspirate of 9 patients after liposuction with the body-jet® have been

incubated with a variety of local anesthetics. Afterwards the vitality of the cells was tested by FACS analysis.

**Conclusion:** Only Lidocaine and Articaine/Epinephrine are applicable for the preparation of infiltration

solution for liposuctions for the purpose of autologous fat harvesting.

M. Keck, J. Janke, K. Ueberreiter: Vitalitätsunterschiede von Präadipozyten unter dem Einfluß verschiedener Lokalanästhetika. Handchir Mikrochir Plast Chir, 2007, 215-219.

# Smooth and gentle on blood and lymph vessels – intact lipocytes

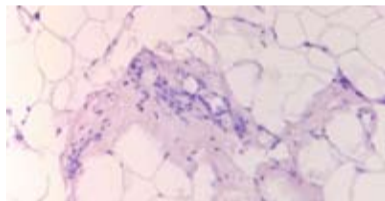
In a new study by Stutz and Krahl published in *Aesthetic Plastic Surgery* in 2008, the authors are concluding:

**"A paradigm shift has occurred with the introduction of water-jet assisted liposuction. For this method no tumescence (firm-elastic infiltration condition with high tissue pressure) is necessary. Likewise no pre-infiltration period for the homogenisation of the adipose tissue is required. The aspiration procedure is started immediately after the anaesthesia has taken effect."**

"The atraumatic, anatomically appropriate procedure of water-jet assisted liposuction (WAL; body-jet®) available today represents a promising treatment for lipoedema patients who



Intact lymph vessels in WAL aspirate (D2-40 antibody staining)

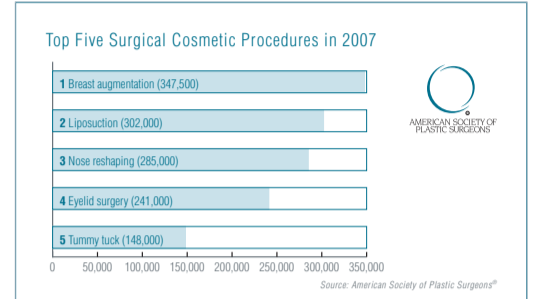


Intact lipocyte complexes in WAL aspirate with strands of collagen-fibrous connective tissue

generally suffer from severe subjective and objective impairment. Liposuction treatment can bring long-term improvement if the operative technique focuses on lymph vessel preservation. Immunohistological analyses show minimal evidence of lymph vessel structures in lipoaspirates."

**"The histological analysis of the aspirates documents a relatively specific removal ("apheresis") of primarily intact lipocytes with low vascular amount. In the lipoaspirates of 28 of the 30 investigated lipoaspirates (patients), the lipocytes were found to be predominantly (>70%) intact."**

Results	
Used local anesthetic	Percentage of vital pre-adipocytes
Prilocain	21,7%
Ropivacain	58,8%
Articain, Epinephrin	65,3%
Lidocain	76,5%
Controls (NaCl)	92,8%



"The analysis of liposuction aspirates from 60 lower extremities obtained from the inner knee area, which represents an especially high-risk region for this type of operation, showed that only minimal or no injury was done to the lymph vessels, if the liposuction procedure was performed strictly parallel to the axis of the lymph collectors.

The immunohistochemical evaluation also confirmed the assumption that a state of tumescence is not required for the water-jet assisted liposuction (WAL) procedure preserving the structural integrity of lymph vessels. It was also proven that, when the WAL

technique is used, the pre-infiltration period for the tumescent fluid did not have to be observed."

J.J. Stutz, D. Krahl: Water Jet-Assisted Liposuction for Patients with Lipoedema: Histologic and Immunohistologic Analysis of the Aspirates of 30 Lipoedema Patients. *Aesth Plast Surg*, 2008.

## Investigation on tissue effects of water-assisted liposuction with the body-jet®

**In a recent investigation at the University of Greifswald, the effect of the body-jet® water spray has been studied on different tissue structures including**

- skin,
- adipose tissue,
- adjacent muscle tissue,
- blood vessels and nerves.

All samples were exposed to the five application ranges (Range 1 to 5) of the body-jet® water jet with a 3.5 mm infiltration cannula. The duration of the saline spray application was 30 seconds within a space of one centimeter in all five ranges. This procedure represents a substantially increased impact on the tissues, as normal application times would only be up to 5 seconds and while moving the cannula. Special attention was focused on the affection of vessels and nerval structures.

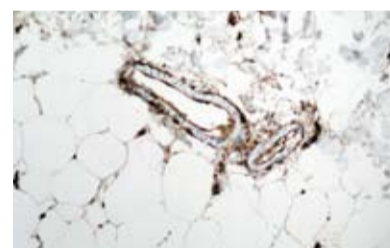
The researchers conclude that **"no vessels or nerval structures were destroyed in the corium/epidermis or in the muscle tissue, even with deep penetration. Our findings indi-**

**cate that no scarring is to be expected after the edema recedes, but a slight reactive fibrosis is possible. This would lead to a tightening of the tissue which could be seen as a firming effect."**

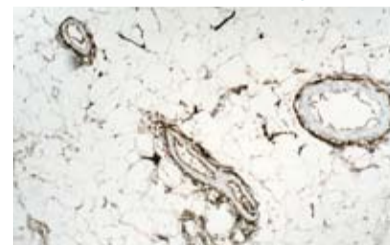The impact of the body-jet® water spray on vascular and nerval structures was analyzed by immunohistochemical staining. Samples representing all three specimens vessels and nerves were marked by CD34 and S100 in order to investigate them for lesions of that structures.

**"In all specimens neither in the dermis nor in the subcutis or adjacent muscles a rupture or lesion of vessels or nerves was observed."**

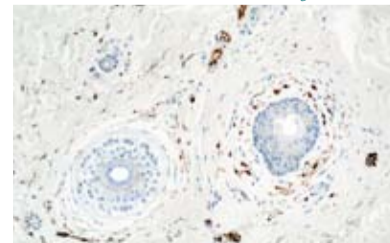
According to the findings, "a large range of action of the water jet was apparent in pure adipose tissue. Connective tissue strands in the subcutis and corium/epidermis impeded the water jet, depending on the thickness of the fibres. Multiple successive connective tissue strands effectively shortened the range of action. No destruction of connective tissue was



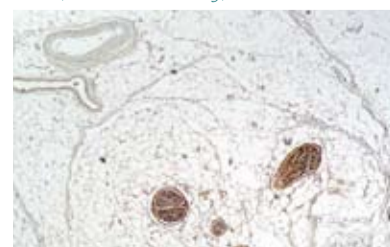
Blood vessels, CD34 endothelium staining, subdermal



Blood vessels, CD34 endothelium staining, subcutis



Nerves, S100 nerval staining, dermis



Nerves, S100 nerval staining submuscular

seen."

"Penetration of water into the corium and/or the epidermis would lead to edema, which would subsequently be drained via the lymph vessels. **The present findings suggest that no scar formation is to be expected."**

"Wherever strands of connective tissue in the subcutis do not cushion the water jet before it reached the muscle layer, thin, diffuse distribution inside and between the individual muscle fibers would occur. Here, too, edema would result from the water penetrating the muscle tissue. This water would drain over the space of a few days through the lymph vessels. However, there could be transient swelling in the muscle fibers and probably slight tenderness in the muscles for a few days."

### ■ Contact:

Professor M. Jünger, M.D.,  
Department of Dermatology,  
Ernst-Moritz-Arndt-University,  
Greifswald; B. Arheilger M.D.,  
University of Rostock, Germany

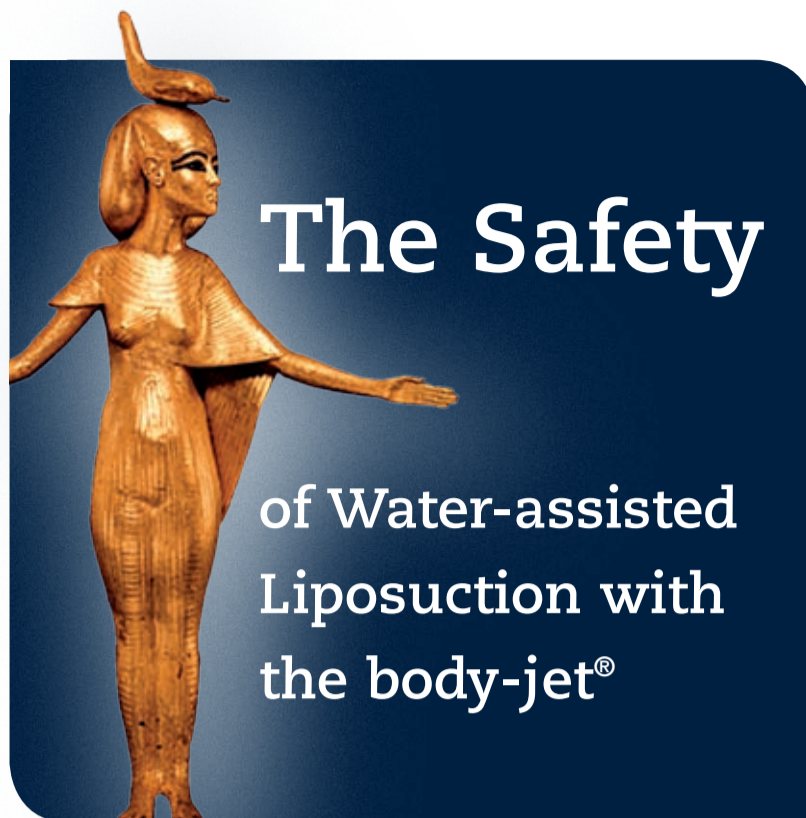
### Clinical Reports on the use of water-assisted lipoplasty (WAL) with the body-jet®

Water-assisted lipoplasty with the body-jet® is being described in the literature for the first time with 280 patients treated from October 1999 on.(1). Since then, the body-jet® is used for lipoplasty in Europe (e.g. in the UK, The Netherlands, Spain, Switzerland, Austria, Germany), in the USA, in Asia (e.g. Japan, Korea, Hong Kong, Singapore), in Australia, Saudi Arabia, Iran, Brazil, Venezuela, Australia and many other countries. Clinical publications and postmarket surveillance reporting do not indicate any case of a major adverse event.

### Clinical data on the safety of WAL with the body-jet®

For WAL with the body-jet® the incidence of complications and adverse events is very low.

In a study by Taufig (1), it is reported that no infections occurred in any of the 280 patients. In one case of 280 a hematoma appeared in the medial area of the knee. In none of



the cases was there a seroma that could be clinically established. The occurrence of ecchymosis was very rare and in these few cases minimal. The previous sensitivity of the skin of the treated areas returned after 3 days to 6 weeks. (1)

In a prospective randomized trial of postoperative pain by Araco et al.

comparing body-jet® WAL („power water-assisted“) and SAL („traditional“) liposuction (2), no postoperative events and no cases of hypovolemia, hemorrhages or infections were reported for WAL and SAL. However, statistical differences were found for ecchymosis measurements, bruising reduction, and pain

measurements, as well as the number of daily analgesic pills.

The authors state that the „comparison of the pain measurements showed a significant difference, with average values 4.8-fold lower for power water-assisted (WAL body-jet®) than for traditional liposuction (SAL) ( $p < 0.05$ ). Additionally, after 4 days, 87% (28/32) of patients treated with power water-assisted liposuction (body-jet®) were completely free of pain versus 3.6% (1/28) of those treated with traditional liposuction.“(2)

„Ecchymosis measurements also were significantly lower for the patients who underwent power water-assisted (body-jet®) rather than traditional liposuction ( $p < 0.05$ ), and the differences were significant in every postoperative measurement.“(2)

Araco et al.: „Both techniques showed a dramatic bruising reduction at postoperative day 5. However, the scores were significantly lower for the power water-assisted liposuction (body-jet®) in every assessment during the first 5 postoperative days.“(2)

In another study by Man and Meyer (3), the authors have found in more than 800 treatments with the body-jet® that

- „It is notable that patient safety has increased considerably, even in extensive procedures.“
- „There is significantly reduced pain-related impairment during



and after the procedure compared with standard tumescent technique. Patients recover quickly and return to normal daily activities rapidly.“

- „Considerably less intraoperative swelling allows the surgeon to realize the target result with greater precision.“
- „Compared with the quantity of tumescent solution used in conventional manual lipoplasty, an average of 20% to 30% was used in preinfiltration“ (when using the body-jet®)
- „The length of time tumescent solution remains in the tissue, as well as the resulting absorption times, are all considerably lower for the recommended infiltration solutions (when using the body-jet®) compared with all other tumescence-based lipoplasty techniques.“ (3)

These last comments may have an aspect regarding discussions on cardiotoxicity of lidocaine and other drugs after high volume infiltration, and on volume-related electrolyte shifts that may occur during traditional liposuction techniques.

#### References:

1. Taufig, A. Z.: Water-Jet Assisted Liposuction. In: Liposuction – Principles and Practice. Springer 2006, 326-330.
2. Araco, A., Gravante, M.D., Araco, F., Delogu, D., Cervelli, V.: Comparison of Power Water-Assisted and Traditional Liposuction: A Prospective Randomized Trial of Postoperative Pain. Aesth. Plast. Surg. 31: 259 – 265, 2007.
3. Man, D.; Meyer, H.: Water Jet-Assisted Lipoplasty. Aesthetic Surgery Journal, May/June 2007, 342 – 346.



## How to use the five ranges (RANGE 1–5) of the body-jet®

As described in the body-jet® Instructions for Use, the application of the fan shaped water spray (saline spray) of the body-jet® can be adjusted in five ranges (RANGE 1–5), according to the plastic surgeons requirements.

RANGE 1 to 5 are all providing the safe administration of saline via the body-jet® cannulae into the adipose tissue in order to loosen and separate the fat cells during the infiltration and aspiration process.

The effect of the body-jet® ranges (RANGE 1-5) on adipose tissue and on vital structures like connective and muscle tissue, blood and lymph vessels, and nerves has been investigated in various histopathological studies.

The results of these studies indicate that in the RANGES 1- 5 of the body-jet® no damage is produced to connective tissue, muscular tissue, blood and lymph vessels, and nerves.

The largest range of action and the maximum loosening (swelling) effect on the fat tissues is achieved at RANGE 2 and RANGE 3, according to a study of the University of Greifswald.

### Rationale on the selection of the body-jet® pressure RANGES

During a lipoplasty procedure the pressure RANGE is selected by the surgeon depending on

1. the phase of the procedure (infiltration phase, aspiration phase),

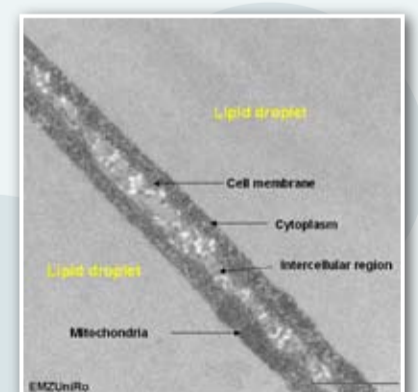
2. the anatomical area that is to be treated,
3. the condition/consistency of the tissue.

Accordingly, the following recommendations on the selection of the RANGES 1–5 are provided, based on the experience of the body-jet® users (publications, study results).

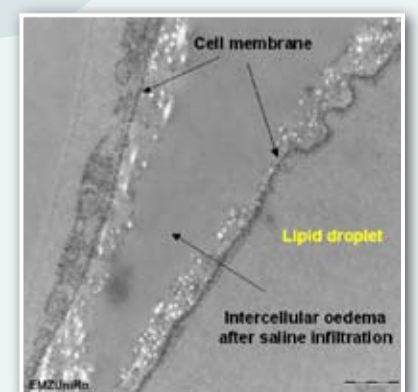
1. Regarding the phase of the procedure: During the infiltration phase (loosening of fat tissue by infiltration of saline solution into the intercellular space), RANGE 2 or RANGE 3 is recommended because of optimum range of action and maximum loosening (swelling) effect. During the following aspiration or suction phase RANGE 1, 2, 3 or 4 are recommended depending on the anatomical area, the condition of the tissue and the desired speed of liposuction.
2. Regarding the anatomical area that is to be treated: In small and/or vulnerable areas (e.g. like the inner knee area or chin area), RANGE 1 or 2 would provide the best and most gentle effect. The RANGES 2, 3 and 4 are applicable for standard procedures of liposuction, e.g. of the upper/lower abdomen, flanks and thighs, according to the surgeons demands.
3. Regarding the condition of the tissue: RANGE 5 would only be used in highly fibrous fat tissues, e.g. during secondary liposuction procedures, and RANGES 2, 3 and 4 for regular tissue conditions. The applied RANGE is increased with increased tissue rigidity.

## The effect of the body-jet® water spray during infiltration/irrigation. The loosening of fat cells – viewed by the electron microscope.

Picture 1  
Adipose tissue – normal finding prior to saline infiltration.



Picture 2  
Oedematous disintegration of the intercellular region. The cell membranes are separated by the saline spray.



# Safe and quick wound cleaning with the new debri-jet®

## International presentation of a new wound debridement

Initial results from a study of the University Dermatology Clinic Greifswald, were presented during the „3rd Congress of the World Union of Wound Healing Societies“ in Toronto and the „18. Conference of the European Wound Management Association“ in Lissabon.

„debri-jet® is a new, effective and hygienic debridement procedure specific for chronic wounds. Using a planar waterjet applied tangentially to the skin, wound debris is loosened quickly, completely and effectively and simultaneously suctioned off. The results show that there is no increased risk of contamination by aerosol formation and infection“.

### Disadvantages of previous surgical methods

- Painfulness and requirement of general anesthesia including problems with anesthetic contraindication
- Delineation of the necrotic margin (necrotic margins persist post-operatively or healthy tissue is being "sacrificed")
- Bleeding that limits visibility, and pain reactions
- Pathogens may remain in the wound and cause recurrent infections.

### Development of the debri-jet®

The application of a pressure-regulated waterjet to the necrotic area facilitates quick and effective wound debridement by substantial

prevention of bleeding combined with immediate removal of debrided material. The necrotic margins are well visualized.

### Advantages of the debri-jet®

- Non-invasive, selective and protective surgical technique: healthy tissue is not removed.
- Better cleaning of the wound: waterjet rinsing cleans more effectively than all other surgical procedures such as scraping, cutting, shaving.
- Removal also of hardened (partially granulated) debris by softening and rinsing off.
- Hygienic removal of loosened wound debris via a closed system.
- Improved wound healing and

increased circulation using the pulsed waterjet alternating with the applied vacuum.

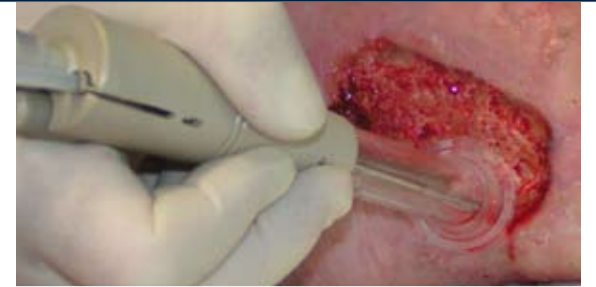### Functional operation of the debri-jet®

A planar waterjet applied tangentially to the wound surface softens and loosens wound debris and necrotic tissue quickly, completely and painlessly, and the dispersed particles can be suctioned off in the same operational step. The device contains a hand piece with a disposable flexible applicator that adjusts to the wound site (see Fig.). Integrated into the hand piece is a pressure sensor. When the applicator is placed on the wound and the opening of the hand piece sealed with a finger, a vacuum is created

that is measured by the sensor. At a defined vacuum the waterjet is produced. When the applicator is removed from the wound or the opening of the hand piece is uncovered the water supply is immediately interrupted. This switching off feature in combination with the flexible applicator minimizes the formation of aerosol and thus avoids contamination and the risk of infection.

### Contact:

Dr. G. Daeschlein, Prof. Dr. M. Jünger, Universitätsklinik der Ernst-Moritz-Arndt Universität Greifswald, Fleischmannstr.42-44, D-17489 Greifswald, Germany



## New surgical treatment option for lymphedema

By J.J. Stutz M.D.

For many years lymphedema was not considered surgically treatable. Only in recent years have increasing numbers of reports from Scandinavia been published that consider surgical measures to be successful in addition to the very important conservative treatment. In a limited number of cases good results can be expected using lymph node transplants. Sufficient lymph nodes must be available on the contralateral side for this procedure.

In 2002 H. Brörson (1) published seven-year results after liposuction for secondary arm lymphedema, achieving almost complete reduction of edema formation using dry liposuction. The author emphasized the improvement in mobility which in these cases could

not be achieved using conservative treatment. In this context M. Földi (2) reported that 5% of 400 lymphedema patients showed no results after a four-week intensive conservative decongestive therapy with CPT (complex physical therapy) but rather continued to increase in size. Quality of life studies with lymphedema patients, however, have recently shown that improved mobility of the extremities contributes far more to the quality of life than edema reduction alone. At this particular point the debulking procedure of liposuction comes into effect. On the basis of our extensive experience with liposuction for lipedema, we employed this technique for non-pitting lymphedema and immunohistologically processed the aspirate, finding no D2-40 antibodies to lymphatic endothelium present. This demon-

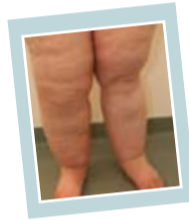strates that waterjet-assisted liposuction does not cause damage to the lymphatic vessels when done correctly. At the same time the edema could, however, be significantly reduced. The number of non-pitting lymphedema patients treated with WAL is admittedly low and the follow-up investigation period is comparatively short, nevertheless the previous results are very promising.

### References:

1. Brörson H. et al.: Complete reduction of arm lymphedema with liposuction – 7 year results. Progress in Lymphology XVIII. Lymphology 2002;35
2. Földi M. Complex Decongestive Physiotherapy In Casley-Smith JR, Progress in Lymphology X. University of Adelaide Press 1985, 165-167

### Contact:

J. J. Stutz M.D. ; Schwerpunktpraxis Lipödem, Thiemitztalstrasse 6, D-95131 Schwarzenbach (www.stutz-dr.com)



## AquaShape® Family

As shown above, water-jet assisted liposuction (WAL) is a particularly gentle method; postoperative pain and bruises are remarkably less with WAL compared to traditional methods. Also, WAL does not require large tumescent pre-infiltration, which helps to reduce the risk of side effects while the contours of the target area remain visible.

Several new products have been developed to support this new approach. Today, the AquaShape® product family consists of the body-jet®, as well as the new AquaShape® mobile and the AquaShape® LipoCollector™.

The AquaShape® mobile\* is a small portable water-jet device. It has been designed to facilitate the entry into the WAL world, and can be used with any suitable vacuum pump. The combination of already available suction equipment with the AquaShape® mobile provides potential for savings. (\*not available in USA)



The most recent member of the AquaShape family is the new AquaShape® LipoCollector™. The LipoCollector™ facilitates collecting up to one liter of filtered fat during a WAL procedure.

### Kontakt:

human med AG  
Wilhelm-Hennemann-Straße 9  
D-19061 Schwerin  
Phone +49 (0) 385-39570-0  
Fax +49 (0) 385-39570-10  
info@humanmed.com  
www.humanmed.com



Simultaneous infiltration and aspiration

### AquaShape® LipoCollector™



### body-jet®



AquaShape® mobile